

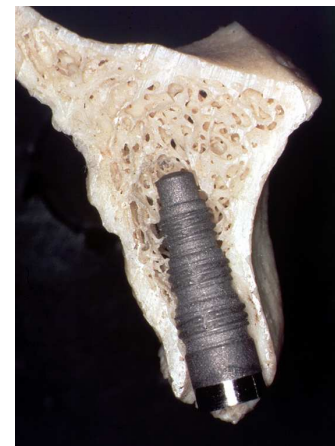Indications, Guidelines and Risk Factors of Early and Immediate Implant Placement with Root-analog Implants: A Literature Review

Dr. med. Dent. Peter Gehrke

Early and immediate implant placement with a root-analog implant design is a well established and proven protocol for placing dental implants. Results of more than 25 years of clinical and statistical data indicate that predictable long-term success can be achieved^{1,2}. Moreover, immediate placement offers significant benefits to both the patient and the clinician. The number of surgeries is minimized and overall treatment time is shortened. Width and height of the alveolar bone is preserved, and a better implant location results in maximal function and esthetic soft tissue support.

Indications for immediate implant placement

Trauma not affecting the alveolar bone
Decay without purulence
Endodontic failure
Severe periodontal bone loss
Residual root
Root fracture



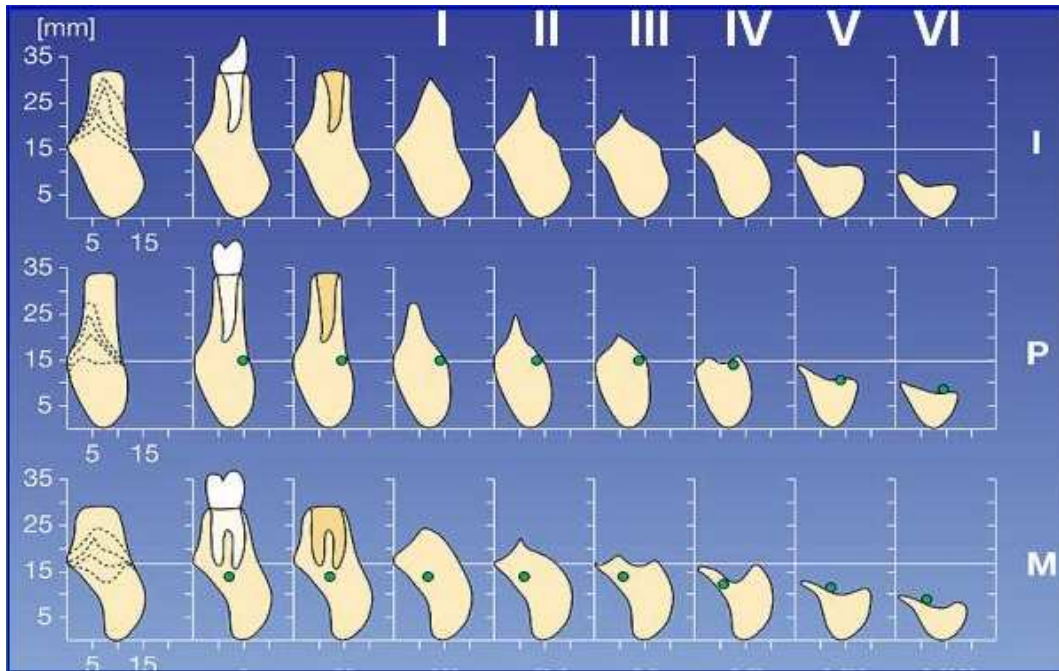
Based upon the literature, the following set of clinical risk factors are collected. Clinical guidelines are given, intended to prevent complications and to maximize the success rate of implants placed into extraction sites.

Pre-surgical implant site evaluation

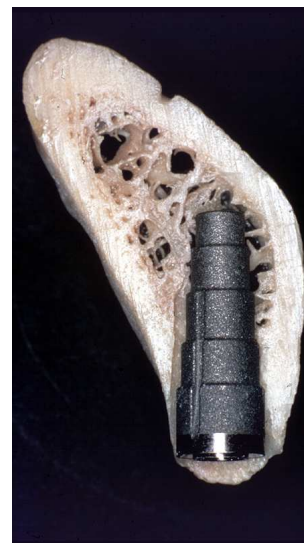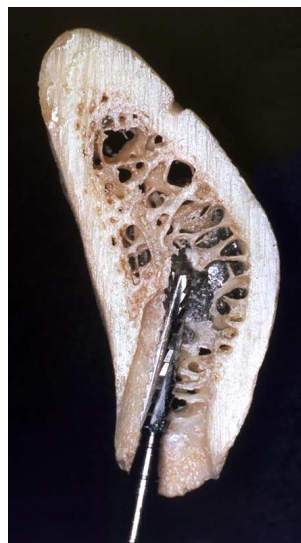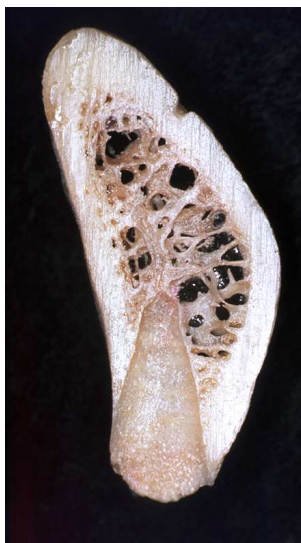In most cases involving immediate implant placement, it will be found that in the apical region of the sockets of anterior teeth and premolars in the maxilla, the bone lamella is significantly thinner labiobuccally than palatally. In the mandible, the lingual aspect of the socket is often thinner than the labial^{3,4,6}. These factors are important in selecting the most appropriate angulation of the pilot drills, which determine the longitudinal axis of the implant site. Failure to do so, may result in perforation of alveolar bone plates during drilling, which will significantly reduce the chance of success.

Prevention of cortical bone lamella

Every effort should be made to minimize bone trauma during surgical removal of the tooth. This can be achieved by sectioning the gingival attachment up to the tooth by means of the periosteal elevator by Schulte⁵. After extraction, the socket should be thoroughly degranulated by careful curettage.



Direct load distribution is only possible over the attached spongy bone due to the different elasticity coefficients of compact and spongy bone. Attachment of the compact bone to the implant occurs during the unloaded healing phase, which is replaced by connective tissue during the functional phase. This can be noted in the marginal area, where especially the facial walls of the alveolar process are of dense bone. Consequently, load distribution takes place at this level due to the higher elasticity coefficient^{3,6,7}. In case of immediate implant placement, these anatomic conditions have to be taken into account. The choice of the implant diameter and size should be performed on the basis of the orofacial and mesiodistal diameters of the alveolus. The most favorable drilling technique can be achieved if the drill for the final implant bed does not get in contact with the facial alveolar wall. Early recessions might occur in case the anatomical situation is not considered.



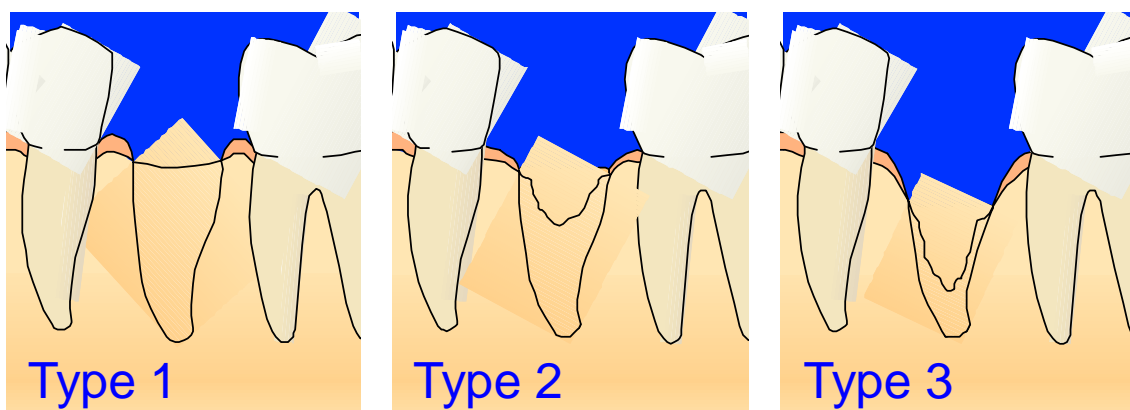
In a statistical evaluation of 221 implants, D'Hoedt ⁸ showed that recessions with simultaneous implant loss are clearly the result of the primarily missing facial bone plate or its damage due to incorrect drilling. A follow-up study of 100 FRIALIT[®]-1 implants by Spörlein et al. ⁹ showed increased mucosal retraction and marginal bone loss around the implant, when the height of the vestibular alveolar is reduced to less than ½ of the implant length.

De Wijs et al. ¹⁰ concludes that immediate implant placement is only indicated when the major part of the labial cortical wall is still intact. The implant survival rate may be severely impaired if insufficient labial bony support is present and implants are placed without additional measures.

Pre-operative classification of extraction sites (Salama & Salama)				
	<i>Bone dimensions</i>	<i>Discrepancy between implant head and neck of adjacent teeth</i>	<i>Gingival recession</i>	<i>Esthetics</i>
TYPE 1	4- or 3-wall socket Minimal resorption Sufficient bone beyond apex	Acceptable	Manageable	Not essential
	▶ Ideal for immediate implant placement			
TYPE 2	Bone dehiscence >5mm	Substantial	Significant	Essential
	▶ Orthodontic extrusive augmentation required			
TYPE 3	Inadequate vertical & buccolingual bone Recession & severe loss of labial bone plate Severe circumferential & angular defects	-	-	-
	▶ Not suitable for immediate implant placement			

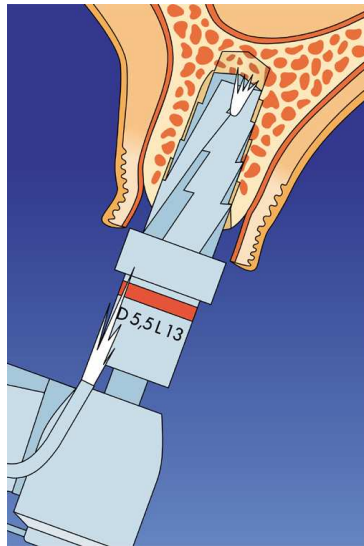
Salama H, Salama M. The role of orthodontic extrusive remodeling placement: A systematic approach to the management of extraction site defects. Int J PeriodonticsRestorative Dent, 13:313-333, 1993

Classification of Extraction Sites



Prevention of thermal drilling trauma

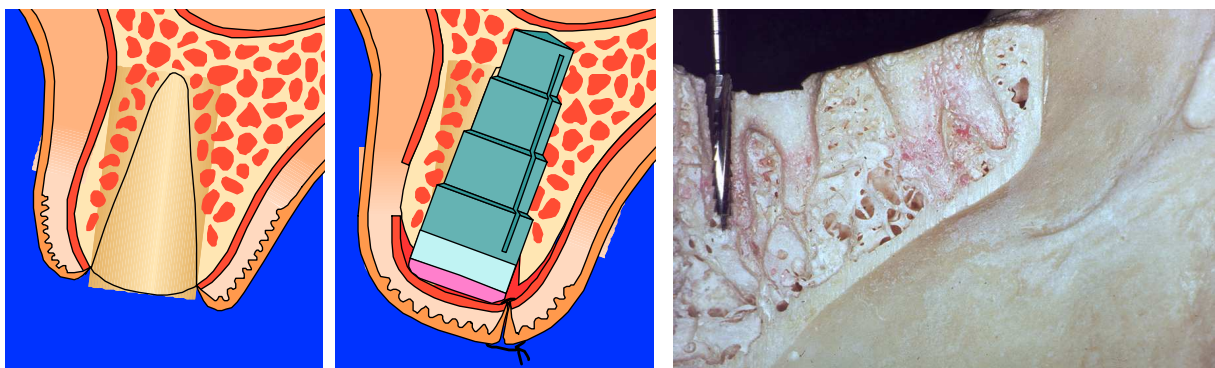
Preventing the destruction of cortical bone lamella is, from a surgical point of view, one of the most important and challenging factors in esthetic implant dentistry. Any kind of mechanical or thermal trauma while preparing the implant site compromises the final outcome. During the osteotomy, the cortical bone layer should be removed very carefully to prevent mechanical trauma of buccal plate fracture. When using wide diameter implants, a thermal trauma by overheating can be avoided if the increase of rotation speed at constant rpm is considered. The rotation speed at the drill circumference rises by the radius, which means that a diameter increase of the receptor site from 3.8 mm to 6.5 mm will lead to an increase of rotation speed at the drill circumference of 68%. Permanent internal irrigation reduces drilling temperature in the bone and prevents heat necrosis. While diameter increased implants could facilitate bypassing poor bone quality by extending laterally into the denser cortical plates, focus should be given to avoid overheating of these dense bone layers by high drill speed and limited irrigation with increasing diameter.



Immediate implant placement

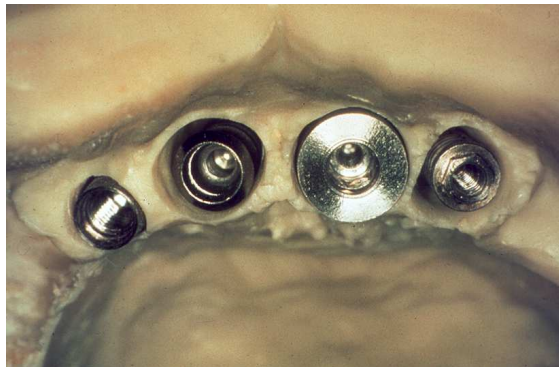
Implants must be placed 3.0 to 5.0 mm beyond the apex in order to gain a maximal degree of stability and as close as possible to the alveolar crest level (0 to 3.0 mm) ¹¹.

In cases of multi-rooted teeth, the implant can be placed in the interseptal bone. If prosthetically manageable, it can be placed in the maxillary palatal socket and in the mandibular mesial or distal socket ¹¹.



Crestal bone-to-implant gap

Schulte and coworkers emphasized that the entire cross section of the socket in the cervical region must be occupied by the implant¹². A gap between the bone and the implant, which may exist with standard cylindrical implants, requires the use of membranes. A wider cervical implant diameter provided by a tapered, stepped implant offers the possibility of obliteration of the alveolar socket at the crestal entrance; better buccal support and helps to preserve root prominence. Furthermore, the implant-to-bone interface is improved, enhancing stability and enabling better positioning. A more esthetically acceptable restoration can thus be fabricated. Therefore the use of an implant design that mimics the shape of a natural tooth root should be therefore considered.



Grafting and the use of a barrier membrane, however, should be considered whenever a circumferential defect of more than 1.0 mm exists around the cervical aspect of the implant¹². Whenever the buccal or labial bone is so thin that the implant can be seen through it or when any acute dehiscence is observed, grafting is also indicated. Various grafting materials can be used to fill this empty space, including autogenous bone, hydroxyapatite and demineralized freeze-dried bone. Autogenous bone material is considered to be the golden standard in grafting materials. The cited literature^{11,13,14} shows no superiority among the bone substitute compounds or their necessity with respect to immediate implantation. In the literature, a consensus can be found stating that the use of a membrane does not necessarily imply better results. On the contrary, membrane exposure may carry complications in its wake.

Once placed in the receptor site, the implant should be totally immobilized without the benefit of graft material. Chances for osseointegration decrease substantially if the implant is mobile.

Inflammation and purulence

If any purulent exudate is present during the course of surgery, the implant placement and/or grafting procedures are not carried out. A delayed procedure is utilized instead. According to some authors^{2,3,4}, the presence of an asymptomatic apical granuloma or cyst is not necessarily a contra indication to an immediate insertion of an implant, but if there are any signs of active inflammation or infection, this must be treated prior to implant surgery. Antibiotic therapy is initiated whenever there is evidence of acute infection.

Special attention must be given implants placed next to natural teeth that are periodontically involved or in patients who are prone to periodontal disease ^{10,11,12}. The same applies for patients under antidepressive treatment. According to studies undertaken so far, a dysfunction of granulocytes might be the cause since, apparently, it prevents a continuous hemidesmosomal epithelial attachment ³.

Primary closure

There is no clear consensus regarding the absolute need for primary closure. Schulte et al ¹ state that a periosteal detachment of the mucosa may lead to a reduction in the underlying alveolar bone, and recommends, therefore, a transmucosal application of a root-analog implant system (anatomic crestal diameter) without incisions. In cases when an implant design is employed which does not mimic the anatomic root form, primary closure of the soft tissues is recommended. The mucogingival condition around the extraction socket may be unfavorable. If primary closure is not achievable, the use of vertical relaxing incisions and/ or horizontal ribbing of the periosteum should be considered ¹⁰. The effects of the different surgical modalities, i.e., a one-stage versus a two-stage procedure, were addressed in a study using primates: No significant difference could be detected ¹⁵.

Temporary restoration post implant placement

The literature advocates the wearing of a prosthesis not earlier than 2 weeks post-implant placement to prevent early trauma to the gingival site above the implant ¹¹. The area should be left without pressure during the entire healing period by an appropriate temporary restoration.

Implants and occlusion

It is essential that the occlusion is adjusted in such a way that the implant is just out of contact with the opposing tooth at a position of lightest occlusal contact of the opposing arches. Occlusal adjustment should also ensure that the implant-supported crown does not bear excessive loads in lateral or protrusive excursions of the mandible. A single implant-supported canine guidance should be avoided. Peri-implant bone loss is more pronounced in implants which are subject to excentric loads due to lateral protrusive movements ⁹.

Dr. Peter Gehrke

Literature

1. Schulte W, d'Hoedt B, Axmann D, Gomez G. The First 15 years of the Tuebinger implant and its further development to the FRIALIT[®]-2 system. Sonderdruck, Z Zahnärztl Implantologie, VIII;2, 1992.
2. Gomez-Roman G, Schulte W, d'Hoedt B, Axman-Krcmar D. The FRIALIT[®]-2 implant system: Five-year clinical experience in single-tooth and immediately postextraction applications. Int J Oral Maxillofac Implants 1997;12:299-309.
3. Schulte W, d'Hoedt B. 13 Jahre Tübinger Implantat aus FRIALIT[®] - Weitere Ergebnisse. , Z Zahnärztl Implantologie, IV, 167-173, 1988.
4. Quayle AA, Cawood J, Howell RA, Eldridge DJ, Smith GA. The immediate or delayed replacement of teeth by permucosal intra-osseous implants: The Tübingen implant system. British Dental Journal; Vol 166, 10, 365-370.
5. Quayle AA, Cawood J, Smith GA, Eldridge DJ, Howell RA. The immediate or delayed replacement of teeth bey permucosal intra-osseous implants: The Tübingen implant system. Part 2: Surgical and restorative techniques. British Dental Journal; Vol 166, 11, 403-410.
6. Lazzara RJ. Immediate implant placement into extraction sites: Surgical and restorative advantages. Int J Perio Rest Dent 1989; Vol 9, 5, 333-344.
7. Schulte W. Klinische und wissenschaftliche Aspekte des Einzelzahnimplantates. Z Zahnärztl Implantologie, III, 135-136, 1987.
8. D'Hoedt B. 10 Jahre Tübinger Implantat aus FRIALIT[®]. Eine Zwischenauswertung der Implantatdaten. Z Zahnärztl Implantol II, 6, 1986
9. Spörlein E, Stein R. Nachuntersuchungen von 100 Tübinger Sofortimplantaten unter Berücksichtigung der parodontalen Situation, der Belastung und der knöchernen Integration.
10. De Wijs FL, Cune MS. Immediate labial contour restoration for improved esthetics: A radiographic study on bone splitting in anterior single-tooth replacement. Int J Oral Maxillofac Implants; 12:686-696, 1997.
11. Schwartz.-Arad D, Chaushu G. The ways and wherefores of immediate placement of implants into fresh extraction sites. A literature review. J Periodontol 1997;68:915-923.
12. Babbush CA. Guidelines for implant placement after immediate extraction. Acedemy of Osseointegration, Academy News Vol 9, 4, 1998.
13. Shirota T, Schmelzeisen R, Neukam F, Matsui Y, Ohno K, Michi K. Immediate insertion of two types of implants into vascularized bone grafts used fro mandibular reconstruction miniature pigs, Oral Surg Oral Med Oral Pathol 1994;77,222-231.
14. Barzilay I, Graser GN, Iranpour B, Natiella JR. Immediate implantation of a pure titanium implant into an extraction socket: Report of a pilot procedure. Int J Orl Maxillofac Implants 1991;6,277-284.
15. Zetterquist L, Anneroth G, Nordenram A. Tissue integration of AL2O3-ceramic dental implants: An experimental study in monkeys. Int J Oral Maxillofac Implants 1991; 6:285-293.
16. Missika P, Abbou M, Rahal B. Osseous regeneration in immediate postextraction implant placement: A literature review and clinical evaluation. Pract Perio Aesthetic Dent. The Regeneration Report 1997; Vol 9,2, 165-174.
17. Salama H, Salama M. The role of orthodontic extrusive remodeling placement: A systematic approach to the management of extraction site defects. Int J Peridontics Restorative Dent 1993;13:313-333.