

# Dental Implantology Update™

The International Forum for Continuing Education

Volume 17, Number 3

March 2006

THOMSON  
AMERICAN HEALTH  
CONSULTANTS

## EDITOR

Arun K. Garg, DMD  
Professor of Surgery  
Director, Center for Dental Implants  
Division of Oral/Maxillofacial Surgery  
University of Miami School of Medicine

## EDITORIAL ADVISORS

Editor Emeritus: Morton L. Perel, DDS, MScD

Hassan M. Abdelwassie, DDS,  
Head of Implantology Department  
Riyadh Dental Center  
Chief Dental Officer  
Riyadh, Saudi Arabia

Charles A. Babbush, DDS, MScD  
Head, Section of Dental Implant  
Reconstructive Surgery  
Mt. Sinai Medical Center  
Cleveland

Fabiola Duarte, DDS  
Private Practice  
Miami, Florida

Charles E. English, DDS  
Staff Prosthodontist  
Veterans Affairs Medical Center  
Augusta, GA

Rick Ferguson, DMD  
Private Practice  
Pembroke Pines, FL

Jack A. Hahn, DDS  
Private Practice  
Cincinnati

Kenneth W.M. Judy, DDS  
Clinical Professor  
Department of Prosthodontics  
University of Pittsburgh School of Dental Medicine

Jack T. Krauser, DMD  
Private Practice, Periodontics and Implantology  
Boca Raton, FL  
Department of Periodontics  
Nova Southeastern College of Dental Medicine  
Davie, FL

Kuy E. Ky, DMD  
Private Practice  
Stockton, CA

Carl E. Misch, DDS, MDS  
Co-Director, Oral Implantology  
University of Pittsburgh School of Dental Medicine

E. Robert Stultz, DMD, MS  
Associate Professor of Periodontics  
University of California, San Francisco  
Private Practice  
San Rafael, CA

## The Syncrystallization Technique: Expediting Rigid Splinting of Immediately Loaded Implants

According to Peter Gehrke, DMD, rigid temporization can have a significant impact on the peri-implant tissue response in immediate implant loading. He explains, "Rigid temporization reduces the mechanical stress exerted on each implant." In this issue of *Dental Implantology Update*, Gehrke describes a prosthetic concept for an accelerated rigid splinting of multiple implants for same-day immediate loading with metal-reinforced provisional restorations using a technique called "Syncrystallization": welding temporary implant abutments with a pre-fabricated titanium bar directly in the oral cavity. He notes that although initial considerations in implant dentistry claimed that the process of osseointegration required on average an undisturbed healing of three months in the mandible and six months in the maxilla,<sup>1-3</sup> early and immediate loading of implants to expedite the restorative outcome has received increasing interest.

### Early Loading of Implants

Some researchers have noted, says Gehrke, that load exerted at the implant interface may interfere with the process of bone healing

and lead to fibrous encapsulation.<sup>4</sup> However, clinical and experimental animal trials have also shown that long-term success of removable and fixed prostheses of immediately loaded dental implants can be achieved.<sup>5-23</sup>

"In addition," he explains, "Initial implant mobility does not inevitably prevent osseointegration."<sup>24</sup> Gehrke notes that, generally, micromotion at the implant interface has to be distinguished from uncontrolled masticatory forces. He says, "The peri-implant bone adjusts its architecture according to its capacity to withstand functional loading, so the strains induced by these loads affect the bone remodeling process." The literature suggests that the magnitude of the load forces between the implant and the bone determines the implant success.<sup>25</sup> Therefore, one key to the success of titanium implants seems to be the adequate bone remodeling at the periphery of the implant.<sup>26</sup> In fact, asserts

### Inside This Issue

Clinically Significant  
Abstracts .....23

DENTAL IMPLANTOLOGY UPDATE IS AVAILABLE ON-LINE  
Go to [www.ahcpub.com/online.html](http://www.ahcpub.com/online.html) for access.



Gehrke, "Microstrain may be a favorable stimulus during the healing period of implants, resulting in an increased bone density."<sup>27-33</sup>

Implants can be loaded early or immediately, if micromovements above a threshold of 100  $\mu\text{m}$  can be avoided during the healing phase.<sup>34-37</sup> Stronger movements would lead to soft-tissue ingrowth at the interface rather than to the desired bone apposition.

Additionally, Gehrke notes, osseointegration can be achieved even with micromovements, but not with so-called macromovements.<sup>38</sup> In spite of the lack of a consistent terminology on the definition of micromovements and macromovements, a movement of 30  $\mu\text{m}$  or less appears to have no adverse effect on integration, while a movement of 150  $\mu\text{m}$  or more results in soft connective tissue apposition to the implant.<sup>39-41</sup> In this context, Gehrke concludes, "It can no longer be assumed that immediate loading per se leads to the fibrous encapsulation of implants."<sup>42</sup>

### **Osseointegration and Accelerated Protocol**

A successful, accelerated protocol for implant rehabilitation depends upon several interrelated factors. Beside accurate pre-surgical diagnostics and treatment planning, as

well as implant macrodesign and microdesign, the adequate fixation and immobility of the implant are of utmost importance to prevent the risk of micromovements related to the surrounding bone. Due to its ability to reduce the mechanical stress exerted on each implant, rigid splinting seems to have a significant impact on the peri-implant tissue response.

Gehrke notes that a high predictability of immediate implant loading with fixed provisional restorations has been shown in several reports.<sup>16,17,43</sup> "This predictability," Gehrke maintains, "indicates that rigid acrylic resin provisional restorations are able to confine the occlusal forces applied to the bone-to-implant interface to a physiological range." He goes on to say that material stability and fracture strength are essential in maintaining the rigidity of provisional restorations on immediately loaded implants over a longer period of time.

He cautions, however, that long-span acrylic resin restorations are subject to flexion and fracture under occlusal forces. This consequence applies in particular for a cross-arch stabilization of multiple implants in the edentulous mandible. Previously described techniques for reinforcement of acrylic resin provisional restorations involve either the

use of a thin wire or fibers throughout the span, or a time-consuming fabrication of a cast metal framework in the laboratory that covers the facial and/or lingual surfaces of the provisional restoration.<sup>26,44-48</sup>

While some researchers have reported a method to reduce prosthetic misfit of implant-supported complete dentures using the combination of intra-oral luting and extra-oral laser welding,<sup>49</sup> others have introduced a time-effective intra-oral welding technique of titanium components for different dental and implant restorations to avoid long laboratory procedures.<sup>50,51</sup>

### **The Syncrystallization Technique**

Gehrke describes the Syncrystallization technique as a clinical and laboratory procedure for a prosthetic concept for an accelerated rigid splinting of multiple implants for same-day immediate loading with metal-reinforced acrylic resin provisional restorations.

A mucoperiosteal flap is elevated after crestal incision. Implants are placed following the respective manufacturers' instructions. A minimum insertion torque of 30 Ncm is used for all implants to assure clinical stability.

First, a facebow transfer and centric relation record are used to

**Dental Implantology Update™** (ISSN 1062-0346) is published monthly by Thomson American Health Consultants, 3525 Piedmont Road N.E., Building Six, Suite 400, Atlanta, GA 30305. Telephone: (404) 262-7436. Periodical postage paid at Atlanta, GA 30374. POSTMASTER: Send address changes to **Dental Implantology Update™**, P.O. Box 740059, Atlanta, GA 30374. Thomson American Health Consultants, in affiliation with Boston University Goldman School of Dental Medicine, offers continuing dental education to subscribers. Each issue of **Dental Implantology Update™** qualifies for 1.5 continuing education units.

**Customer Service:** (800) 688-2421. Fax: (800) 284-3291. Hours of operation: 8:30 a.m. - 6 p.m. Monday - Thursday; 8:30 a.m. - 4:30 p.m. Friday, EST.

E-mail: [customerservice@ahcpub.com](mailto:customerservice@ahcpub.com). World Wide Web: [www.ahcpub.com](http://www.ahcpub.com).

Subscription rates: U.S., \$599 per year. Students, \$320 per year. To receive student/resident rate,

order must be accompanied by name of affiliated institution, date of term, and the *signature* of program/residency coordinator on institution letterhead. Orders will be billed at the regular rate until proof of student status is received. Outside U.S., add \$30 per year, total prepaid in U.S. funds. Discounts are available for multiple subscriptions. For pricing information, call Steve Vance at (404) 262-5511. Missing issues will be fulfilled by customer service free of charge when contacted within one month of the missing issue date. Back issues, when available, are \$100 each. For 18 continuing education units, add \$96 per year.

Opinions expressed are not necessarily those of this publication. Mention of products or services does not constitute endorsement. Clinical, legal, tax, and other comments are offered for general guidance only; professional counsel should be sought for specific situations.

Copyright © 2006 by Thomson American Health Consultants. **Dental Implantology Update™** is a trademark of Thomson American

Health Consultants. The trademark **Dental Implantology Update™** is used herein under license. All rights reserved. Reproduction, distribution, or translation of this newsletter in any form or incorporation into any information retrieval system is strictly prohibited without express written permission. For reprint permission, please contact Thomson American Health Consultants. Address: P.O. Box 740056, Atlanta, GA 30374. Telephone: (800) 688-2421.

Vice President/Group Publisher: **Brenda Mooney**, (404) 262-5403, ([brenda.mooney@thomson.com](mailto:brenda.mooney@thomson.com)).

Editorial Group Head: **Lee Landenberger**, (404) 262-5483, ([lee.landenberger@thomson.com](mailto:lee.landenberger@thomson.com)).

Managing Editor: **Paula Cousins**, (816) 960-3730, ([paula.cousins@thomson.com](mailto:paula.cousins@thomson.com)).

**THOMSON**  
  
**AMERICAN HEALTH CONSULTANTS**



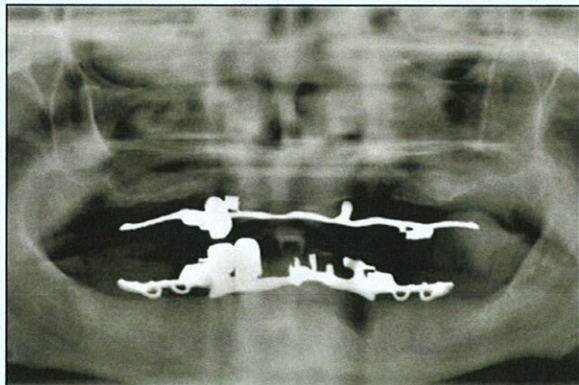


Figure 1: Pre-operative orthopantomograph X-ray.

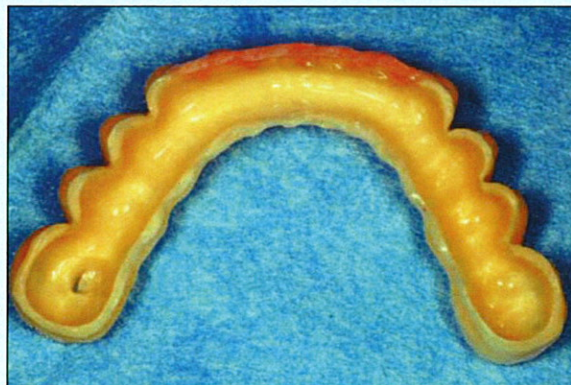


Figure 2: Hollow acrylic resin provisional restoration prior to relining.

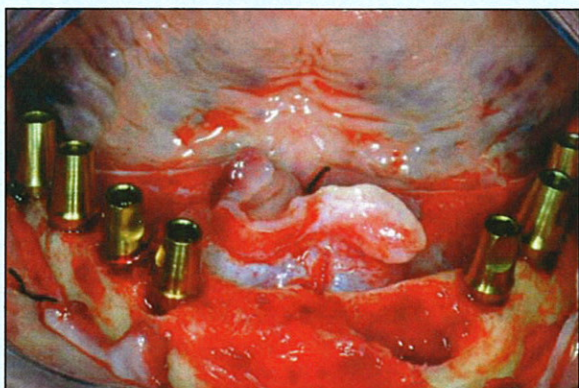


Figure 3: Clinical view after implant placement.



Figure 4: Occlusal view of intraoral welding process: Welding clamps holding implant abutment and titanium bar.

mount the diagnostic casts on a semi-adjustable articulator. Subsequently, a diagnostic wax-up for a preliminary provisional fixed restoration is fabricated and converted to autopolymerizing resin. After surgical placement of the implants, temporary titanium abutments are connected to them.

If implants with an internal hexagon are used, the connection should be rounded before the welding process, avoiding non-retrievability of the welded piece in case of pronounced disparallelism. The abutments consist of two parts (abutment and retaining screw) to ensure retrievability of the welded

piece. A pre-existing or prepared flat surface area serves as the welding point. A titanium bar is shaped following the curvature of the implants positioned. At this point, temporary titanium implant abutments (TempBase, Dentsply Friadent, Germany) are welded with the titanium bar in the oral cavity, using the Syncrystallization unit (System Argon Control, Implamed, Cremona, Italy).

The welding process is electrical and protected by an argon gas supply (Syncrystallization). The equipment allows the welding of metallic elements directly in the mouth. The two elements to be welded are

placed between the two electrodes of a welding clamp. The energy contained in a previously unloaded battery of capacitors is transferred to the electrodes of the welding clamp. Current flowing through the contact points, being in contact with the parts to weld, warms up to the point of fusion, achieving a solid, welded junction.

The welding cycle is subdivided into three stages: Pre-gas phase, welding phase, and post-gas phase. Whereas the pre-gas phase allows an oxygen-free welding point prior to the actual fusion, the post-gas phase ensures the absence of oxygen and subsequent oxidation during



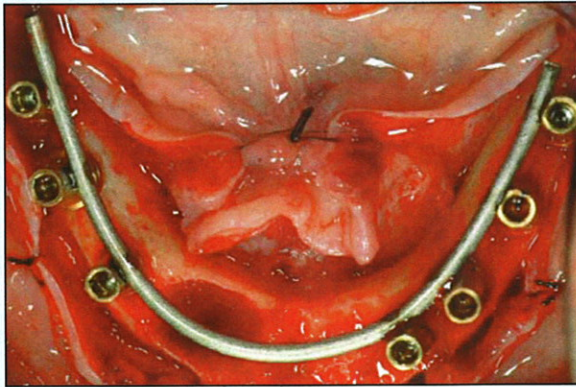


Figure 5: Intra-orally welded titanium bar.



Figure 6: Extra-oral view of welding spot.

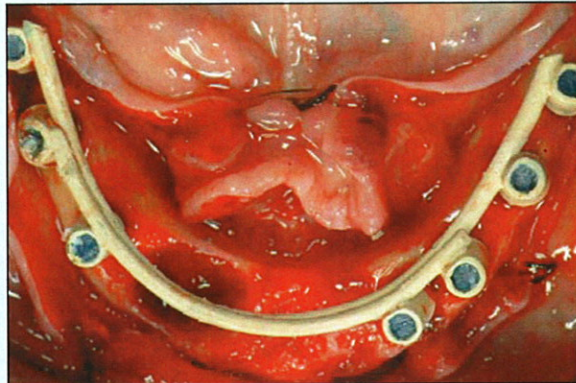


Figure 7: Try-in of welded abutment-bar construction after opaque application.

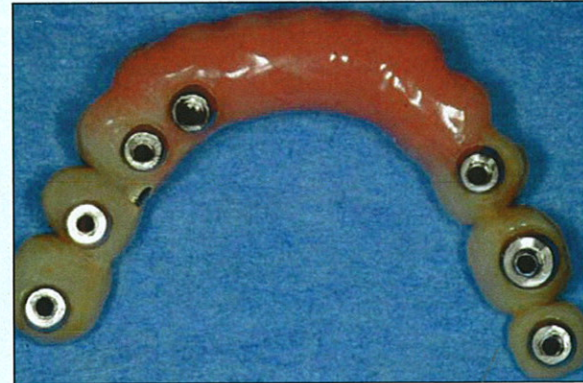

Figure 8: Provisional metal reinforced restoration after relining, trimming, and polishing; ready to be delivered two hours later.

cooling. A barely perceptible sound can be perceived during use of the Syncrystallization unit. Welding of the pieces takes only a fraction of a second. The process is carried out without producing any heat, causing no discomfort to the patient or damage to surrounding tissues.

Finally, the prosthetic framework, created by welding the titanium bar to the implant abutments, is removed and opaque is applied to avoid metal shining through the acrylic resin. The provisional restoration is relined, trimmed, polished, and screw-retained the same day. Occlusal contact is avoided in centric and lateral excursions.

Figures 1-10 depict the Syncrystallization technique, from pre-operative to postoperative orthopantomograph X-ray. Figures 11 and 12 provide magnified views of the welding joint.

### Conclusion

"Prosthodontic challenges in fixed immediate temporization of multiple implants," Gehrke says, "can be both safely and predictably addressed when using the Syncrystallization technique." In addition to rigid implant splinting, the provisional restoration serves as a guide for the final superstructure

while aesthetics and phonetics are evaluated for patient acceptance. The temporization procedure can be significantly accelerated and causes minimal discomfort or interruption in function and cosmetics for the patient. In comparison to mere acrylic superstructures, a significant reduction of deformation and strain within metal-reinforced provisional restorations could be detected.

Gehrke concludes, "Although using the Syncrystallization unit needs no specific training, an excellent collaboration between the experienced restorative surgeon and the laboratory team is desirable." The advantages of the new technique



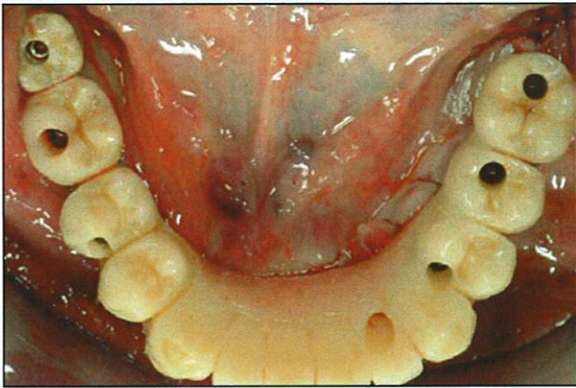


Figure 9: Occlusal view of screw-retained mandibular metal-reinforced provisional restoration in situ.

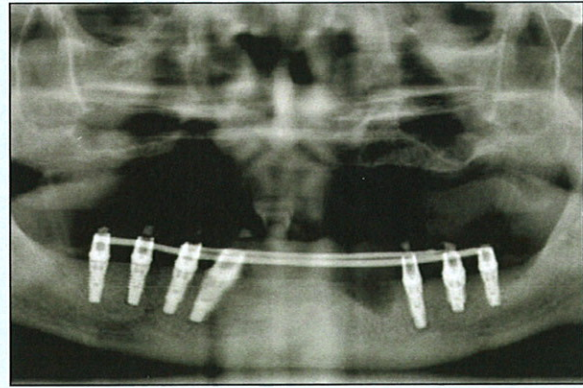


Figure 10: Immediate postoperative orthopantomograph X-ray.




Figure 11: Cross-section of a welding joint at 20-fold magnification. Temporary abutment (round section above) and titanium bar (straight section below).

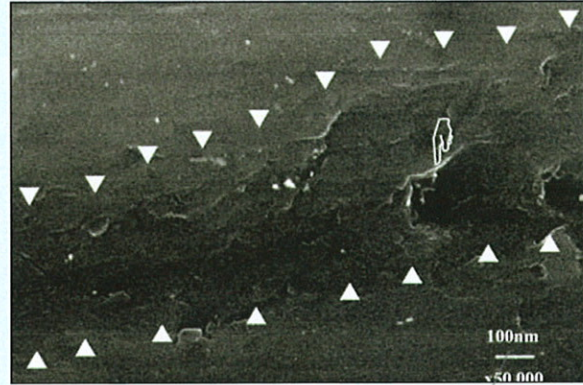


Figure 12: Welding joint at 50,000-fold magnification. Only minor porosity can be detected.

include reduction of treatment time for immediate temporization at stage one surgery, predictable fixation and immobility of implants in the early stages of bone healing, and less time spent for repairing provisional restorations as a result of no, or less frequent, fracture.

## References

1. Brånemark PI, Breine U, Adell R, et. Intraosseous anchorage of dental prosthesis. I. Experimental studies. *Scand J Plastic Recon Surg* 1969; 3:81-100.
2. Albrektsson T, Brånemark PI, Hansson HA, et al. Osseointegrated titanium implants. Requirements for ensuring a long-lasting, direct bone-to-implant anchorage in man. *Acta Orthop Scand* 1981; 52:155-170.
3. Brånemark PI. Osseointegration and its theoretical background. *J Prosthetic Dentistry* 1983; 50:399-410.
4. Donath K, Laass M, Gunzl HJ. The histopathology of different foreign-body reactions in oral soft tissue and bone tissue. *Virchows Arch A Pathol Anat Histopathol* 1992; 420: 131-137.
5. Ledermann PD. New Ledermann screw. *Quintessenz* 1988; 39:799-815.
6. Schnitman PA, Wohrle PS, Rubenstein JE. Immediate fixed interim prostheses supported by two-stage threaded implants: Methodology and results. *J Oral Implantol* 1990; 16:96-105.
7. Salama H, Rose LF, Salama M, et al. Immediate loading of bilaterally splinted titanium root-form implants in fixed prosthodontics—a technique reexamined: Two case reports. *Int J Periodontics Restorative Dent* 1995; 15:344-361.
8. Ledermann PD. More than 20 years of experience with immediate loading of implant borne cantilever prostheses in the interforaminal region. *Zeitschrift für Zahnärztliche Implantologie* 1996; 12:123-136.
9. Chiapasco M, Gatti C, Rossi E,



transfer. In: Laney WR, Tolman DE, eds. *Tissue Integration in Oral, Orthopaedic and Maxillofacial Reconstruction*. Chicago: Quintessence; 1992:108-124.

37. Brunski JB. Avoid pitfalls of overloading and micromotion of intraosseous implants. *Dent Implantol Update* 1993; 4:77-81.

38. Cameron H, Macnab I, Pilliar R. Porous surfaced Vitallium staples. *S Afr J Surg* 1972; 10:63-70.

39. Pilliar RM, Lee JM, Maniopoulos C. Observations on the effect of movement on bone ingrowth into porous-surfaced implants. *Clin Orthop Relat Res* 1986; (208):108-113.

40. Brunski JB. Biomechanical factors affecting the bone-dental implant interface. *Clin Mater* 1992; 10:153-201.

41. Szmukler-Moncler S, Salama H, Reingewirtz Y, et al. Timing of loading and effect of micromotion on bone-dental implant interface: Review of experimental literature. *J Biomed Mater Res* 1998; 43:192-203.

42. Szmukler-Moncler S, Piattelli A, Favero GA, et al. Considerations preliminary to the application of early and immediate loading protocols in dental implantology. *Clin Oral Implants Res* 2000; 11:12-25.

43. Rodrigues AH, Morgano SM, Guimaraes MM, et al. Laboratory-processed acrylic resin provisional restoration with cast metal substructure for immediately loaded implants. *J Prosthet Dent* 2003; 90:600-604.

44. Saba S. Design of a cast bar reinforced provisional restoration for the management of the interim phase in implant dentistry. *J Can Dent Assoc* 1999; 65:160-162.

45. Binkley CJ, Irvin PT. Reinforced heat-processed acrylic resin provisional restorations. *J Prosthet Dent* 1987; 57:689-693.

46. Emtiaz S, Tarnow DP. Processed acrylic resin provisional restoration with lingual cast metal framework. *J Prosthet Dent* 1998; 79:484-488.

47. Burns DR, Beck DA, Nelson

SK; Committee on Research in Fixed Prosthodontics of the Academy of Fixed Prosthodontics. A review of selected dental literature on contemporary provisional fixed prosthodontic treatment: Report of the Committee on Research in Fixed Prosthodontics of the Academy of Fixed Prosthodontics. *J Prosthet Dent* 2003; 90:474-497.

48. Hamza TA, Rosenstiel SF, Elhosary MM, et al. The effect of fiber reinforcement on the fracture toughness and flexural strength of provisional restorative resins. *J Prosthet Dent* 2004; 91:258-264.

49. Longoni S, Sartori M, Davide R. A simplified method to reduce prosthetic misfit for a screw-retained, implant-supported complete denture using a luting technique and laser welding. *J Prosthet Dent* 2004; 91:595-598.

50. Hruska AR. Intraoral welding of pure titanium. *Quintessence Int* 1987; 18:683-688.

51. Mondani PL, Mondani PM. The Pierluigi Mondani intraoral electric solder. Principles of development and explanation of the solder using syncrystallization. *Riv Odontostomatol Implantoprotesi* 1982; (4):28-32.

**Contact:** Peter Gehrke, DMD, Bismarckstrasse 27, Ludwigshafen, Germany, 67059; e-mail: dr-gehrke@dr-dhom.de. ■

## Clinically Significant

### ABSTRACTS

Nagasao T, Miyamoto J, Jin H, et al. **The dynamics in implantation for patients with clefts.** *Cleft Palate Craniofac J* 2006; 43:84-91.

The objective of this study was to investigate the stresses and strains of an endosseous dental

implant in patients with different types of cleft palate in a finite element model.

Seven three-dimensional (3D) maxillary models were designed on a personal computer according to computed tomography slice data obtained from seven dry skulls. Next, computer-aided modification was performed on each model to produce three other 3D models with different cleft patterns. Thus, four model types with different cleft patterns were designed and termed norm (without cleft), alveolar (only alveolar cleft), palatal (only palatal cleft), and complete (complete cleft). An implant was embedded into the molar region of each model, and 300-N vertical and 50-N horizontal loads were applied to simulate mastication. Under these conditions, the stresses occurring at the implant-bone interface were calculated by finite element analysis.

Different stress patterns were observed between the models with a palatal cleft (palatal and complete) and those without palatal cleft (norm and alveolar). Regarding vertical load application/greater stresses occurred in palatal and complete types than in norm and alveolar types. On application of a horizontal load, though the stresses did not show quantitative difference, their vector patterns differed.

In patients with palatal clefts, characteristic stress patterns occur on the bone-implant interface during mastication. This should be taken into consideration when performing an implant treatment in patients with clefts. ▼

Yamamoto H, Shibata Y, Tachikawa T, et al. **In vivo performance of two different hydroxyapatite coatings on titanium prepared by discharging in electrolytes.** *J Biomed Mater Res B Appl Biomater* 2005 Dec 16; [Epub ahead of print].

This study reports a discharging method for bone-like carbonated